






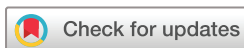# Cam morphology is associated with MRI-defined cartilage defects and labral tears: a case-control study of 237 young adult football players with and without hip and groin pain

Joshua Heerey <sup>1</sup>, Joanne Kemp <sup>1</sup>, Rintje Agricola,<sup>2</sup> Ramya Srinivasan,<sup>3</sup> Anne Smith,<sup>4</sup> Tania Pizzari,<sup>1</sup> Matthew King <sup>1</sup>, Peter Lawrenson <sup>5</sup>, Mark Scholes <sup>1</sup>, Thomas Link,<sup>3</sup> Richard Souza,<sup>3,6</sup> Sharmila Majumdar,<sup>3</sup> Kay Crossley<sup>1</sup>

**To cite:** Heerey J, Kemp J, Agricola R, *et al.* Cam morphology is associated with MRI-defined cartilage defects and labral tears: a case-control study of 237 young adult football players with and without hip and groin pain. *BMJ Open Sport & Exercise Medicine* 2021;**7**:e001199. doi:10.1136/bmjsem-2021-001199

► Additional supplemental material is published online only. To view, please visit the journal online (<http://dx.doi.org/10.1136/bmjsem-2021-001199>).

Accepted 8 November 2021



© Author(s) (or their employer(s)) 2021. Re-use permitted under CC BY-NC. No commercial re-use. See rights and permissions. Published by BMJ.

For numbered affiliations see end of article.

## Correspondence to

Dr Kay Crossley;  
[k.crossley@latrobe.edu.au](mailto:k.crossley@latrobe.edu.au)

## ABSTRACT

**Objective** Football players are at risk of developing hip osteoarthritis (OA). Cam morphology (present in almost two of every three football players) may explain this heightened risk, but there is limited research on its role in hip OA development in younger athletes. Knowledge of this relationship will advance our understanding of the aetiology of hip OA in football players. We aimed to study the relationship between cam morphology size and MRI-defined cartilage defects and labral tears, and if this relationship differs by symptomatic state in young adult football players.

**Methods** For this case-control study, 182 (288 hips) symptomatic (hip and/or groin pain >6 months and positive flexion-adduction-internal-rotation (FADIR) test) and 55 (110 hips) pain-free football players (soccer or Australian football) underwent anteroposterior and Dunn 45° radiographs, and 3-Tesla MRI. Cam morphology size was defined using alpha angle, and cartilage defects and labral tears were scored semiquantitatively. Presence, location and score (severity) of cartilage defects and labral tears were determined. Each participant completed the International Hip Outcome Tool 33 and Copenhagen Hip and Groin Outcome Score.

**Results** Greater alpha angle was associated with cartilage defects (OR 1.03, 95% CI 1.01 to 1.04) and labral tears (OR 1.02, 95% CI 1.01 to 1.04). Greater alpha angle was associated with superolateral cartilage defects (OR 1.03, 95% CI 1.02 to 1.05) and superior labral tears (OR 1.03, 95% CI 1.02 to 1.05). The association of alpha angle with MRI-defined cartilage defects and labral tears was no greater in football players with symptoms than in those without ( $p=0.189-0.937$ ).

**Conclusion** Cam morphology size was associated with cartilage defects and labral tears in young adult football players with and without pain. This study provides evidence that cam morphology may contribute to the high prevalence of hip OA in football players. Prospective studies of football players are now needed to establish if cam morphology causes progression of cartilage defects and labral tears and development of hip OA.

## Key messages

### What is already known?

- Playing football is associated with an up to ninefold greater odds of developing hip OA in later life.
- Cam morphology is present in almost two-thirds of football players.
- Cam morphology is a risk factor for hip OA in middle-aged to older populations, but its role in the development of early hip OA features (cartilage defects and labral tears) in young adult football players is unclear.

### What are the new findings?

- Cam morphology (greater alpha angle) was associated with the presence, location and severity of MRI-defined cartilage defects and labral tears in young adult football players
- The relationship between cam morphology size and MRI-defined cartilage defects and labral tears (presence, location and severity) was no greater in young adult football players with hip and/or groin pain (including a positive FADIR test) than in those without pain.

## INTRODUCTION

Hip osteoarthritis (OA) is a leading cause of hip pain, disability and socioeconomic burden.<sup>1</sup> Traditionally considered to have an idiopathic aetiology, recent evidence suggests that mechanical factors play an important role in hip OA development.<sup>2-4</sup> For example, playing football is associated with an up to ninefold greater odds of developing hip OA.<sup>5</sup> This may be related to the presence of cam morphology, which is characterised by extra bone at the anterolateral head-neck junction,<sup>3</sup> and present in almost two-thirds of football players.<sup>6,7</sup> Associations between cam morphology and hip OA have been

demonstrated consistently across studies of non-athletic people, aged 50 years and older.<sup>2-8</sup> However, this body of evidence adds little to our understanding of the role that cam morphology plays in hip OA development in younger football players.

In football players, cam morphology likely develops during adolescence.<sup>9-10</sup> It is possible that early OA changes, which might include the pathological interaction between cam morphology and chondrolabral structures, first begins during this period. However, in a recent cross-sectional study, cartilage composition did not differ between adolescent football players with and without cam morphology.<sup>11</sup> It is more likely that features of early OA (ie, cartilage defects and labral tears) gradually develop and only present in football players with cam morphology from early adulthood. However, little is known about the relationship between cam morphology and MRI-defined cartilage defects and labral tears in young adult football players.<sup>12</sup>

Our previous work showed that many football players with cam morphology, as well as those with cartilage defects and/or labral tears, do not report symptoms.<sup>7,13</sup> However, no studies have examined the relationship between cam morphology and cartilage defects and/or labral tears, and symptoms in football players. The genesis of hip-related symptoms could relate to the presence, location and/or severity of cartilage and labral damage specifically in football players with cam morphology. If the relationship between cam morphology, intra-articular features and symptoms were better clarified, it may improve our understanding of the aetiology of hip OA.

The aims of this study were to: (1) examine the relationship between cam morphology size and the presence and severity of MRI-defined cartilage defects and labral tears in young adult football players with and without hip and/or groin pain; (2) examine the relationship between cam morphology size and the presence of cartilage defects and labral tears in specific anatomical subregions in football players with and without hip and/or groin pain and (3) investigate if the association between cam morphology size and cartilage defects and labral tears is stronger in young adult football players with hip and/or groin pain.

## METHODS

### Study design and recruitment

This case-control study was nested within the femoroacetabular impingement and hip osteoarthritis cohort (FORCe) study. The FORCe study is a prospective study investigating changes to hip joint structures over a 2-year period in 184 subelite football players (soccer or Australian football) with long-standing hip and/or groin pain (>6 months) aged between 18 and 50 years, described previously.<sup>7-14</sup> A convenience sample of 55 pain-free subelite football players aged between 18 and 50 years were recruited to match the mean age and sex distribution of the FORCe study and serve as control participants.<sup>7</sup> Symptomatic and control participants competing in the

same league/competition level were recruited between August 2015 and October 2018 from sporting clubs or via online and print advertising, with recruitment undertaken in Melbourne and Brisbane, Australia. The data for this study are taken from baseline examination. All study participants provided written informed consent prior to being involved in this study.

### Study participants

#### Hip and/or groin pain group

Eligibility criteria are presented in online supplemental table 1. Briefly, inclusion criteria were self-reported hip and/or groin pain (>6 months in duration) that was >3 and <8 on an 11-point numerical pain rating scale with football or football specific movements; participation in ≥2 football sessions (training or competition) per week; a positive flexion-adduction-internal-rotation (FADIR) test, that elicited hip (anterior, lateral or posterior) and/or groin pain in at least one hip. Exclusion criteria were history of previous pathological hip conditions and radiographic hip OA (ie, Kellgren and Lawrence (KL) ≥2).

#### Control group

For control participants, inclusion criteria were no prior history of hip and/or groin pain; participation in ≥2 football sessions per week; and a negative FADIR test in both hips (see online supplemental table 1). Exclusion criteria were similar to the hip and/or groin pain group, but also included previous lower limb surgery (eg, knee reconstruction).

### Radiographs

Standardised supine anteroposterior (AP) pelvis and bilateral Dunn 45° radiographs were obtained for each participant. For the AP radiograph, the participant was placed in supine, with both legs internally rotated 15°. For the Dunn 45° radiograph, the hip was flexed to 45°, abducted 20° and positioned in neutral rotation.

### Cam morphology

For each radiograph, one investigator (JH), who was blinded to clinical findings, positioned a set of landmark points to the surface of the proximal femur and acetabulum using statistical shape modelling software (ASM toolkit, Manchester University, Manchester, UK), followed by automatic calculation of the alpha angle (MATLAB V.7.1.0. MathWorks, Natick, Massachusetts, USA). Dichotomisation of continuous measures should be avoided in epidemiological studies.<sup>15</sup> Thus, we present alpha angle as a continuous measure. For intraobserver reliability, the intraclass correlation coefficients (ICCs) for alpha angle were 0.92 and 0.93 for AP and Dunn 45°, respectively.<sup>7</sup> Interobserver reliability ICCs were 0.76 for AP and 0.93 for Dunn 45°.<sup>7</sup>

### MRI acquisition and scoring

All participants underwent a non-contrast 3 Tesla MRI (Phillips Ingenia, The Netherlands). Participants were positioned in supine, hips fixed in internal rotation and

neutral abduction/adduction with patient positioning aids, and a 32-channel torso coil placed over the hips and pelvis, with right and left hips imaged separately. The MRI sequences acquired were coronal proton density (PD) spectral attenuated inversion recovery (SPAIR), sagittal PD SPAIR and oblique axial PD SPAIR (online supplemental table 2).

Each MRI was evaluated using the Scoring of Hip Osteoarthritis with MRI (SHOMRI) scoring system by one musculoskeletal radiologist (RS) with 8 years' experience who was blinded to clinical and radiographic findings. Morphological changes to cartilage and the labrum are important features of early hip OA,<sup>16</sup> and were selected as outcome measures. Cartilage defects were graded from 0 to 2 (0=no defect, 1=partial defect or 2=full thickness defect) and scored in 10 (4 acetabular and 6 femoral) subregions, providing a total cartilage score per hip of 0–20. A cartilage defect was present if a partial or full thickness defect was reported. For the superolateral, superomedial, anterior and posterior subregions, acetabular and femoral cartilage defects were combined. Labral abnormalities were graded from 0 to 5 (0=normal or normal variant (eg, aplasia, hypoplasia), 1=abnormal signal or fraying, 2=simple tear, 3=labrocantilage separation, 4=complex tear or 5=maceration) and scored in 4 subregions (anterior, posterior, anterosuperior and superior), with a total labral score per hip of 0–20. A labral tear was scored as present when graded  $\geq 2$ . The SHOMRI subregions were used to describe the location of cartilage defects and labral tears for each hip. Intraobserver reliability was determined by 20 randomly selected hips being reread 2 weeks after the initial grading. Intraobserver agreement for cartilage defects and labral tears had prevalence adjusted bias adjusted kappa values of 0.76 (kappa 0.62) and 0.80 (kappa 0.77), respectively.<sup>13</sup>

### Patient-reported outcome measures

For each participant, demographic characteristics were recorded and the International Hip Outcome Tool 33 (iHOT33)<sup>17</sup> and Copenhagen Hip and Groin Outcome Score (HAGOS)<sup>18</sup> were completed. The iHOT33 and HAGOS are recommended for young adults with hip and/or groin conditions<sup>19 20</sup> and each contain several unique questions.<sup>21</sup> The inclusion of both questionnaires provides a comprehensive understanding of hip and/or groin pain burden.

### Statistical analysis

Data analyses were performed with Stata/IC V.16.1 for Mac (StataCorp). All analyses were undertaken at a per hip level, with cam morphology (evaluated as a continuous (alpha angle) variable) considered as the independent variable and cartilage defects or labral tears as the dependent variable. For the first study aim, logistic regression (presence of cartilage defects and labral tears) and negative binomial regression (severity of cartilage defects and labral tears) models with generalised estimating equations (GEE) (to allow for within-person correlation between

right and left hip data) were used to determine whether cam morphology was associated with cartilage defects and labral tears. Models were checked for linearity of continuous alpha angle associations by graphical assessment and testing models with nonlinear terms for superior fit. Odds ratios (OR) and incidence rate ratios (IRR) with associated 95% CIs and p values are presented. For the second study aim, logistic regression models with GEE were used to estimate the relationship between cam morphology and the presence of cartilage defects and labral tears in specific anatomical subregions (cartilage defects=superolateral, superomedial and lateral; labral tears=superior and anterosuperior), with results presented as OR with 95% CI and p values. The remaining subregions for cartilage defects (inferior, anterior and posterior) and labral tears (anterior and posterior) were not compared statistically as there was a low prevalence in all hips. The probability (presence and location) and score (severity) of cartilage defects and labral tears were estimated for increases in size of cam morphology (5° increase in alpha angle) from regression models. For study aim three, an interaction term (alpha angle $\times$ symptoms) was incorporated into all regression models to test if the association between cam morphology and cartilage defects or labral tears was stronger in those football players with symptoms. For all analyses, symptomatic and control hips were combined, and models adjusted for sex, age, body mass index, KL grade and symptoms.

### Patient and public involvement

Patients and/or the public were not involved in the design, conduct, reporting or dissemination plans of this research.

## RESULTS

### Participants

Of the 184 eligible football players, 182 (288 hips, 20% female, median age 26 (IQR 7), 50% soccer) were included (table 1 and online supplemental figure 1). The two excluded participants had incomplete MRI data. In 74 of 182 symptomatic football players, the contralateral hip was excluded as it did not fulfil study inclusion criteria. Twelve participants (22 hips with hip and/or groin and 2 control hips) had AP, but not Dunn 45° radiographs due to protocol deviations. A further two hips (two participants) with hip and/or groin pain were excluded due to the presence of hip OA. A standing and not a supine AP pelvis radiograph was taken in seven participants (14 hips) with hip and/or groin pain, with these radiographs included in the overall analysis. Fifty-five football players (110 hips, 25% female, median age 26 (IQR 8), 55% soccer) formed the control group (table 1 and online supplemental figure 2).

### Association between cam morphology and presence of cartilage defects and labral tears

Greater AP and Dunn 45° alpha angle were associated with cartilage defects (table 2). Greater AP and Dunn 45°



**Table 1** Demographic characteristics, radiographic and patient-reported outcome measures for hip and/or groin pain and control participants

	Hip and/or groin pain group (n=182)	Control group (n=55)
Demographic characteristics		
Age, year	26.0 (23, 30)	26.0 (23, 31)
Sex, women (%)	37 (20)	14 (25)
Height, m	1.79 (1.73, 1.85)	1.79 (1.72, 1.85)
Weight, kg	77.9 (72, 86)	78.7 (67, 89)
BMI, kg/m <sup>2</sup>	24.2 (23, 26)	24.3 (22, 27)
Football code, % soccer	50	55
Training/competition session (per week), %		
Two to 3 sessions	89	82
≥4 sessions	11	18
Duration of symptoms, months*	24 (18, 49)	–
Imaging measures		
KL grade, hips (%)		
Grade 0	277 (96)	105 (95)
Grade 1	11 (4)	5 (5)
Alpha angle (AP), deg	52 (45, 76)	48 (43, 78)
Alpha angle (Dunn 45°), deg†	69 (56, 79)	65 (55, 75)
Patient-reported outcome measures		
iHOT33	64 (50, 74)	98 (97, 100)
HAGOS–Symptoms‡	61 (51, 68)	100 (93, 100)
HAGOS–Pain‡	75 (65, 83)	100 (100, 100)
HAGOS–ADL‡	80 (70, 95)	100 (100, 100)
HAGOS–sports/recreation‡	66 (52, 77)	100 (100, 100)
HAGOS–PA§	63 (38, 75)	100 (100, 100)
HAGOS–QOL‡	60 (50, 70)	100 (100, 100)

Values are presented as %, or median (IQR).

\*181 symptomatic participants.

†274 symptomatic hips/108 control hips.

‡176 symptomatic participants/54 control participants.

§175 symptomatic participants/54 control participants.

ADL, activities of daily living; AP, anteroposterior; BMI, body mass index; HAGOS, Hip and Groin Outcome Score; iHOT33, International Hip Outcome Tool 33; KL, Kellgren and Lawrence; PA, physical activity; QOL, quality of life.

alpha angle were associated with labral tears (table 3). Figure 1 and online supplemental table 3 specify the probability of a cartilage defect or labral tear for a 5° increase in AP and Dunn 45° alpha angle.

#### Association between cam morphology and location of cartilage defects and labral tears

Greater AP (adjusted OR (aOR) 1.03, 95% CI 1.02 to 1.05;  $p<0.001$ ) and Dunn 45° alpha angle (aOR 1.04, 95% CI 1.02 to 1.05;  $p<0.001$ ) were associated with superolateral,

but not superomedial or lateral cartilage defects (online supplemental table 4).

Greater AP (aOR 1.03, 95% CI 1.02 to 1.05;  $p<0.001$ ) and Dunn 45° alpha angle (aOR 1.03, 95% CI 1.01 to 1.04;  $p=0.003$ ) were associated with superior, but not anterosuperior labral tears (online supplemental table 5). The probability of a superolateral cartilage defect and superior labral tear for every 5° increase in alpha angle is presented in figure 2 and online supplemental table 6.

#### Association between cam morphology and severity of cartilage defects and labral tears

Greater AP (adjusted IRR (aIRR) 1.01, 95% CI 1.00 to 1.02;  $p=0.017$ ), but not Dunn 45° alpha angle was associated with worse cartilage score (online supplemental table 7). Greater AP (aIRR 1.01, 95% CI 1.00 to 1.01;  $p<0.001$ ) and Dunn 45° alpha angle (aIRR 1.01, 95% CI 1.00 to 1.01;  $p=0.021$ ) were associated with worse labral score (online supplemental table 8). Predicted cartilage and labral scores for every 5° increase in alpha angle is presented in online supplemental figure 3 and table 9.

#### Interaction between cam morphology and symptoms (hip and/or groin pain alongside a positive FADIR test)

There was no evidence for a difference in size of association between cam morphology and cartilage defects or labral tears between football players with and without symptoms (online supplemental table 10–15).

#### DISCUSSION

Cam morphology (greater alpha angle) was associated with MRI-defined cartilage defects and labral tears in football players. Cam morphology was mostly associated with superolateral cartilage defects and superior labral tears. We did not observe a difference in the size of association between cam morphology and cartilage defects or labral tears in football players with and without symptoms.

#### Cam morphology and MRI-defined cartilage defects and labral tears in football players

Playing football is associated with an up to ninefold greater odds of developing hip OA in later life,<sup>5</sup> but the underlying mechanism for this relationship has remained unclear. Cam morphology is a risk factor for hip OA in middle-aged to older populations,<sup>4 22 23</sup> and thought to contribute to early hip disease in active football players.<sup>7</sup> Our findings suggest that cam morphology size is associated with cartilage defects and labral tears in young football players (median age, 26), but that this relationship with joint damage is no greater in football players with symptoms (including a positive FADIR test) than in those without.

A dose–response association was found between cam morphology and MRI-defined intra-articular features in football players, similar to reports from people undergoing hip arthroscopy.<sup>24–26</sup> For example, a 10° increase in AP alpha angle was associated with a small

**Table 2** Association between alpha angle and cartilage defects (presence) for all hips (hip and/or groin pain and control)

Radiographic variable	No of hips	Cartilage defect	
		Unadjusted OR (95% CI) p value	Adjusted OR (95% CI)* p value
Alpha angle (AP view)	398	1.03 (1.02 to 1.04) <0.001	1.03 (1.01 to 1.04) <0.001
Alpha angle (Dunn 45° view)	382	1.02 (1.01 to 1.04) 0.001	1.02 (1.00 to 1.04) 0.024

\*Adjusted for age, sex, body mass index, KL grade and symptoms  
AP, anteroposterior; KL, Kellgren and Lawrence.

increase in the odds of having a cartilage defect (30%) or labral tear (20%). It is unclear if associations of this magnitude are of clinical relevance. It also remains unknown if the effect of cam morphology remains the same during the ageing process in football players and/or if cartilage and labral damage—which may be signs early OA—is expedited into hip OA in those with cam morphology.

Combined with others,<sup>27–30</sup> our findings in football players might implicate cam morphology as a risk factor for early hip OA. The progression of joint disease may involve the interplay between bony parameters, hip and/or pelvic biomechanics and muscle function, and be unrelated to symptoms. Future well designed multicentre prospective cohort studies (to allow sharing of data) of athletes are needed to determine the role of cam morphology in symptom genesis and/or worsening, and hip OA development.

#### Location of MRI-defined cartilage defects and labral tears

Our semiquantitative MRI data support a pathomechanical model of femoroacetabular impingement syndrome with cam morphology, where premature contact between the proximal femoral head-neck junction and acetabular rim is associated with region-specific cartilage and labral damage.<sup>3</sup> Higher alpha angle was associated with superolateral cartilage defects and superior labral tears, whereby, a 10° increase in AP alpha angle was associated with 1.34-fold increase in the odds of having either MRI

finding. Mechanical abutment between the femoral head-neck junction and acetabulum may occur throughout the full arc of flexion in hips with larger cam morphology,<sup>31</sup> which over time, could induce prolonged impingement and resultant damage to chondrolabral structures. Our findings suggest that MRI-defined chondrolabral damage corresponds to the location of cam morphology, and that the presence of this damage is associated with the size of cam morphology rather than the presence of symptoms.

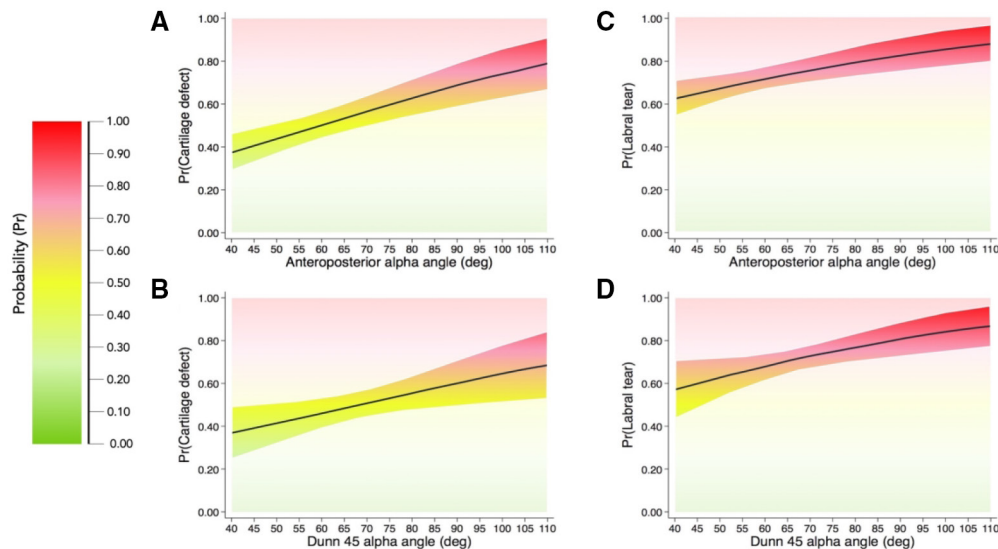
#### Why do some football players with cam morphology and MRI-defined cartilage defects and labral tears remain asymptomatic and others do not?

Not all football players with cam morphology and coexisting cartilage defects or labral tears had hip and/or groin pain. The question then emerges, what factors differ in football players with and without pain? For many, their symptoms may emanate from structures external to the hip joint, even in the presence of cam morphology and intra-articular features. For example, clinical groin pain entities, such as adductor-related groin pain are present in close to 70% of players with long-standing symptoms.<sup>32 33</sup> Also, we examined cam morphology in isolation from acetabular morphology and/or rotational aspects such as acetabular and femoral version. It could be that symptoms are only generated when specific femoral and acetabular bony parameters exist together alongside cartilage defects or labral tears.<sup>1 34</sup> However, consideration of structural

**Table 3** Association between alpha angle and labral tears (presence) for all hips (hip and/or groin pain and control)

Radiographic variable	No of hips	Labral tear	
		Unadjusted OR (95% CI) p value	Adjusted OR (95% CI)* p value
Alpha angle (AP view)	398	1.02 (1.01 to 1.04) 0.004	1.02 (1.01 to 1.04) 0.005
Alpha angle (Dunn 45° view)	382	1.02 (1.00 to 1.04) 0.013	1.02 (1.00 to 1.04) 0.017

\*Adjusted for age, sex, body mass index, KL grade and symptoms  
AP, anteroposterior; KL, Kellgren and Lawrence.

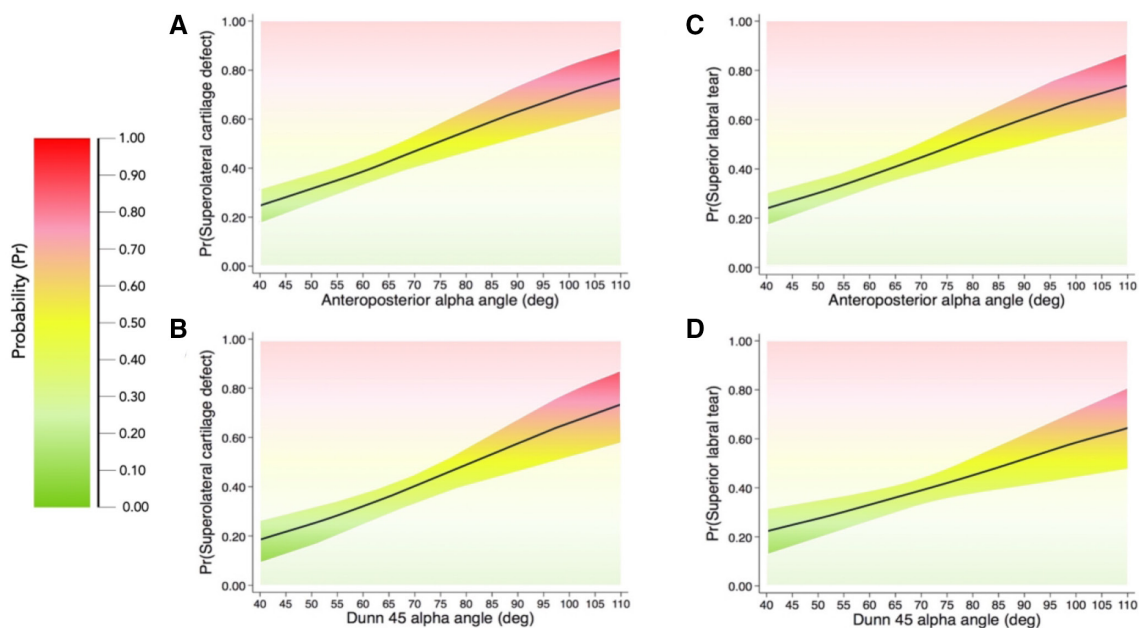


**Figure 1** Probability plots from 0 (0%) to 1 (100%) of cartilage defects and labral tears (presence) for values of alpha angle in 5° increments in all hips (hip and/or groin pain and control hips combined). (A) Cartilage defect (anteroposterior alpha angle); (B) cartilage defect (Dunn 45° alpha angle); (C) labral tear (anteroposterior alpha angle); (D) labral tear (Dunn 45° alpha angle).

factors alone fails to appreciate the complex aetiology of pain.<sup>35</sup> Joint injury (eg, labral tears) may occur without pain<sup>36 37</sup> and pain may persist despite the completion of tissue healing.<sup>35</sup> Long-standing hip and/or groin pain is often accompanied by altered psychological state, disturbed sleep and social limitations, which can all modulate pain levels.<sup>35 38 39</sup> A symptomatic football player with cam morphology and MRI-defined intra-articular features requires a comprehensive assessment that considers the contribution of structural and non-structural factors.

### Clinical implications

Young adult football players with cam morphology are likely to display MRI-defined cartilage defects and labral tears; however, the severity and extent of structural damage appears to be no greater in football players with symptoms (including a positive FADIR test) than in those without pain. Cam morphology is a risk factor for hip OA,<sup>4 22 23</sup> but not all people with cam morphology develop symptoms<sup>40</sup> or display progression of joint disease.<sup>4</sup> Treatments targeting



**Figure 2** Probability plots from 0 (0%) to 1 (100%) of cartilage defects and labral tears (location) for values of alpha angle in 5° increments in all hips (hip and/or groin pain and control hips combined). (A) Superolateral cartilage defect (anteroposterior alpha angle); (B) superolateral cartilage defect (Dunn 45° alpha angle); (C) superior labral tear (anteroposterior alpha angle); (D) superior labral tear (Dunn 45° alpha angle).



cam morphology (eg, surgery) can improve patient-reported outcome measures, but it is unknown if they are needed to slow the progression of joint disease in football players, without prospective studies.

The way that medical information is communicated can influence patients' understanding of their diagnosis and treatment preferences. Information provided by healthcare practitioners can lead patients to believe their hip and/or groin pain and associated disability is solely caused by damaged intra-articular joint structures observed on imaging (eg, labral tears).<sup>41</sup> This can result in patients seeking interventions that 'cure' structural joint damage, such as hip arthroscopy. When communicating hip joint imaging findings, clinicians should use consistent and non-threatening language, and provide patients with accurate epidemiological (ie, prevalence of hip joint imaging findings in asymptomatic populations of similar, age, sex and activity level) and prognostic information.<sup>42</sup>

### Limitations

First, a number of different clinical entities may elicit symptoms in football players.<sup>43</sup> We did not evaluate our football players for the presence specific clinical entities, including adductor-related, iliopsoas-related, pubic-related or inguinal-related groin pain, and some football players may have had coexisting conditions that contributed to their symptoms. The FADIR test is sensitive, but not specific to intra-articular hip conditions.<sup>44</sup> It is possible that some football players did not have pain generated by intra-articular conditions. We used a single imaging parameter (ie, alpha angle) to define cam morphology. Other imaging measures (eg, femoral neck-shaft angle) are associated with symptoms and might play a role in the pathogenesis of cartilage defects and labral tears.<sup>45–46</sup> The SHOMRI is a valid and reliable semi-quantitative measure for grading intra-articular features involved in hip OA.<sup>47</sup> Not all intra-articular structures involved in the pathogenesis of hip OA are evaluated by the SHOMRI<sup>48</sup> and other methods (ie, quantitative MRI) can be used to evaluate cartilage and labral integrity.<sup>30–49</sup> It is possible that a relationship may exist between cam morphology and SHOMRI features not reported in this study (eg, bone marrow oedema, subchondral cysts), as found in previous studies.<sup>30–52</sup> A single musculoskeletal radiologist completed the SHOMRI scoring for all hips and we did not determine inter-rater reliability. As a result, we may over or under-report the severity of MRI-defined features. The accuracy of contrast-enhanced MRI is superior to unenhanced MRI for assessment of cartilage and labral conditions,<sup>53–54</sup> but high-resolution, unenhanced 3 Tesla MRI can provide comparable accuracy to contrast-enhanced approaches.<sup>55–57</sup> Furthermore, contrast-enhanced MRI is associated with risk and not appropriate for asymptomatic populations.<sup>58</sup> Our cohort consisted of young-adult football players who responded to study adverts or participated in information sessions;

therefore, they may not be representative of all young adults participating in football. Despite the large sample size of this study (n=237) it is possible that we were underpowered to detect an interaction effect.<sup>59</sup> The case-control design of this study precludes inferences of a cause-and-effect relationship between cam morphology and MRI-defined features.

### CONCLUSION

In young adult football players, cam morphology size was associated with MRI-defined cartilage defects and labral tears. This relationship was no greater in football players with symptoms than without, suggesting a complex relationship between cam morphology, specific intra-articular features and symptoms. Clinicians who treat young football players with cam morphology should be careful with what they say and do—we do not yet know enough about the long-term consequences of cam morphology on joint structure and symptoms.

### Author affiliations

<sup>1</sup>La Trobe Sport and Exercise Medicine Research Centre, School of Allied Health, Human Services and Sport, La Trobe University, Bundoora, Victoria, Australia

<sup>2</sup>Department of Orthopaedic Surgery, Erasmus MC, University Medical Center Rotterdam, Rotterdam, The Netherlands

<sup>3</sup>Department of Radiology and Biomedical Imaging, University of California-San Francisco, San Francisco, California, USA

<sup>4</sup>School of Physiotherapy and Exercise Science, Curtin University, Perth, Western Australia, Australia

<sup>5</sup>School of Health and Rehabilitation Sciences, The University of Queensland, Brisbane, Queensland, Australia

<sup>6</sup>Department of Physical Therapy and Rehabilitation Science, University of California-San Francisco, San Francisco, California, USA

**Twitter** Joshua Heerey @jheerey, Joanne Kemp @JoanneLKemp, Tania Pizzari @DrTaniaPizzari and Matthew King @mattgmk1

**Acknowledgements** The authors would like to thank the staff at Imaging at Olympic Park and Qscan radiology clinics, as well as the study participants, who all assisted in the collection of data for this study. MJS is supported by the La Trobe University Postgraduate Research Scholarship. KC is supported in part by funding from the National Health and Medical Research Council (NHMRC) project grant (GNT1088683).

**Contributors** JH contributed to conception and design of the study, acquisition of data, analysis and interpretation of data, writing and revising the manuscript and is the guarantor of the study. RS contributed to scoring of MRIs and interpretation of data, revision of the manuscript and final approval of the article. AJS contributed to conception and design of the study, statistical analysis and interpretation of data, revision of the manuscript and final approval of the article. RA, JK, RS, TP, TL and SM contributed to conception and design of the study, revision of the manuscript and final approval of the article. MK, PRL and MJS contributed to conception and design of the study, acquisition of data, revising the manuscript and final approval of the article. KC contributed to conception and design of the study, obtaining funding, analysis and interpretation of data, revision of the manuscript and final approval of the article.

**Funding** The study was supported by an Australian National Health and Medical Research Council (NHMRC) project grant (grant number 1088683).

**Disclaimer** The funding body did not have a role in study design, collection, analysis and interpretation of data, writing of the manuscript or decision to submit the manuscript for publication.

**Competing interests** None declared.

**Patient consent for publication** Not applicable.

**Ethics approval** Ethics approval was obtained from the La Trobe University Human Ethics Committee (HEC 15-019 and HEC16-045) and the University of Queensland Human Ethics Committee (2015000916 and 2016001694).



**Provenance and peer review** Not commissioned; externally peer reviewed.

**Data availability statement** Data (MRI and patient-reported outcome measures) are available on reasonable request. Suitability of data request and access to data will be determined by the corresponding author.

**Open access** This is an open access article distributed in accordance with the Creative Commons Attribution Non Commercial (CC BY-NC 4.0) license, which permits others to distribute, remix, adapt, build upon this work non-commercially, and license their derivative works on different terms, provided the original work is properly cited, appropriate credit is given, any changes made indicated, and the use is non-commercial. See: <http://creativecommons.org/licenses/by-nc/4.0/>.

#### ORCID iDs

Joshua Heerey <http://orcid.org/0000-0001-8691-1830>

Joanne Kemp <http://orcid.org/0000-0002-9234-1923>

Matthew King <http://orcid.org/0000-0003-0470-5924>

Peter Lawrenson <http://orcid.org/0000-0002-6479-6840>

Mark Scholes <http://orcid.org/0000-0001-9216-1597>

#### REFERENCES

- Murphy NJ, Eyles JP, Hunter DJ. Hip osteoarthritis: etiopathogenesis and implications for management. *Adv Ther* 2016;33:1921–46.
- Casartelli NC, Maffiuletti NA, Valenzuela PL, et al. Is hip morphology a risk factor for developing hip osteoarthritis? A systematic review with meta-analysis. *Osteoarthritis Cartilage* 2021;29:S106345842100813X:1252–64.
- Ganz R, Parvizi J, Beck M, et al. Femoroacetabular impingement: a cause for osteoarthritis of the hip. *Clin Orthop Relat Res* 2003;417:112–20.
- Agricola R, Heijboer MP, Bierma-Zeinstra SMA, et al. Cam impingement causes osteoarthritis of the hip: a nationwide prospective cohort study (check). *Ann Rheum Dis* 2013;72:918–23.
- Vigdorich JM, Nepple JJ, Eftekhar N, et al. What is the association of elite sporting activities with the development of hip osteoarthritis? *Am J Sports Med* 2017;45:961–4.
- Mosler AB, Crossley KM, Waarsing JH, et al. Ethnic differences in bony hip morphology in a cohort of 445 professional male soccer players. *Am J Sports Med* 2016;44:2967–74.
- Heerey J, Agricola R, Smith A, et al. The size and prevalence of bony hip morphology do not differ between football players with and without hip and/or groin pain: findings from the force cohort. *J Orthop Sports Phys Ther* 2021;51:115–25.
- van Buuren MMA, Arden NK, Bierma-Zeinstra SMA, et al. Statistical shape modeling of the hip and the association with hip osteoarthritis: a systematic review. *Osteoarthritis Cartilage* 2021;29:607–18.
- Palmer A, Fernquest S, Gimpel M, et al. Physical activity during adolescence and the development of CAM morphology: a cross-sectional cohort study of 210 individuals. *Br J Sports Med* 2018;52:601–10.
- van Klij P, Heijboer MP, Ginai AZ, et al. Cam morphology in young male football players mostly develops before proximal femoral growth plate closure: a prospective study with 5-year follow-up. *Br J Sports Med* 2019;53:532–8.
- Fernquest S, Palmer A, Pereira C, et al. The response of hip joint cartilage to exercise in children: an MRI study using T2-mapping. *Cartilage* 2020;194760352093118:194760352093118.
- Márquez WH, Gómez-Hoyos J, Gallo JA, et al. Prevalencia de lesiones del labrum Y del cartilago articular de la cadera en imagen POR resonancia magnética simple 3 T de futbolistas profesionales asintomáticos. *Revista Española de Cirugía Ortopédica y Traumatología* 2019;63:77–85.
- Heerey JJ, Srinivasan R, Agricola R, et al. Prevalence of early hip oa features on MRI in high-impact athletes. The femoroacetabular impingement and hip osteoarthritis cohort (force) study. *Osteoarthritis Cartilage* 2021;29:323–34.
- Crossley KM, Pandy MG, Majumdar S, et al. Femoroacetabular impingement and hip osteoarthritis cohort (force): protocol for a prospective study. *J Physiother* 2018;64:55.
- Altman DG, Royston P. The cost of dichotomising continuous variables. *BMJ* 2006;332:1080:1080.1.
- Siebelt M, Agricola R, Weinans H, et al. The role of imaging in early hip oa. *Osteoarthritis Cartilage* 2014;22:1470–80.
- Mohtadi NGH, Griffin DR, Pedersen ME, et al. The development and validation of a self-administered quality-of-life outcome measure for young, active patients with symptomatic hip disease: the International hip outcome tool (IHOT-33). *Arthroscopy* 2012;28:595–610.
- Thorborg K, Hölmich P, Christensen R, et al. The Copenhagen hip and groin outcome score (HAGOS): development and validation according to the COSMIN checklist. *Br J Sports Med* 2011;45:478–91.
- Impellizzeri FM, Jones DM, Griffin D, et al. Patient-reported outcome measures for hip-related pain: a review of the available evidence and a consensus statement from the International hip-related pain research network, Zurich 2018. *Br J Sports Med* 2020;54:848–57.
- Thorborg K, Tjissen M, Habets B, et al. Patient-Reported outcome (pro) questionnaires for young to middle-aged adults with hip and groin disability: a systematic review of the Clinimetric evidence. *Br J Sports Med* 2015;49:812.
- Oji NM, Jansson H, Bradley KE, et al. Comparing patient-reported outcome measurements for femoroacetabular impingement syndrome. *Am J Sports Med* 2021;49:1578–88.
- Saberi Hosnijeh F, Zuiderwijk ME, Versteeg M, et al. Cam deformity and acetabular dysplasia as risk factors for hip osteoarthritis. *Arthritis Rheumatol* 2017;69:86–93.
- Thomas GER, Palmer AJR, Batra RN, et al. Subclinical deformities of the hip are significant predictors of radiographic osteoarthritis and joint replacement in women. A 20 year longitudinal cohort study. *Osteoarthritis Cartilage* 2014;22:1504–10.
- Dumont GD, Ergen TJ, Pacana MJ, et al. Patient-specific factors are associated with severity of chondrolabral injury in patients with femoroacetabular impingement. *Knee Surg Sports Traumatol Arthrosc* 2020;28:3376–81.
- Kapron AL, Aoki SK, Weiss JA, et al. Isolated focal cartilage and labral defects in patients with femoroacetabular impingement syndrome may represent new, unique injury patterns. *Knee Surg Sports Traumatol Arthrosc* 2019;27:3057–65.
- Redmond JM, Gupta A, Hammarstedt JE, et al. Labral injury: radiographic predictors at the time of hip arthroscopy. *Arthroscopy* 2015;31:51–6.
- Anwander H, Melkus G, Rakhra KS, et al. T1p MRI detects cartilage damage in asymptomatic individuals with a CAM deformity. *J Orthop Res* 2016;34:1004–9.
- Bittersohl B, Steppacher S, Haamberg T, et al. Cartilage damage in femoroacetabular impingement (FAI): preliminary results on comparison of standard diagnostic vs delayed gadolinium-enhanced magnetic resonance imaging of cartilage (dGEMRIC). *Osteoarthritis Cartilage* 2009;17:1297–306.
- McGuffin WS, Melkus G, Rakhra KS, et al. Is the contralateral hip at risk in patients with unilateral symptomatic CAM femoroacetabular impingement? A quantitative T1p MRI study. *Osteoarthritis Cartilage* 2015;23:1337–42.
- Reichenbach S, Leunig M, Werlen S, et al. Association between cam-type deformities and magnetic resonance imaging-detected structural hip damage: a cross-sectional study in young men. *Arthritis Rheum* 2011;63:4023–30.
- Fernquest S, Arnold C, Palmer A, et al. Osseous impingement occurs early in flexion in cam-type femoroacetabular impingement: a 4D CT model. *Bone Joint J* 2017;99-B:41–8.
- Hölmich P. Long-standing groin pain in sportspeople falls into three primary patterns, a "clinical entity" approach: a prospective study of 207 patients. *Br J Sports Med* 2007;41:247–52.
- Taylor R, Vuckovic Z, Mosler A, et al. Multidisciplinary assessment of 100 athletes with groin pain using the Doha agreement: high prevalence of adductor-related groin pain in conjunction with multiple causes. *Clin J Sport Med* 2018;28:364–9.
- Bouma HW, Hogervorst T, Audenaert E, et al. Can combining femoral and acetabular morphology parameters improve the characterization of femoroacetabular impingement? *Clin Orthop Relat Res* 2015;473:1396–403.
- Hainline B, Turner JA, Caneiro JP, et al. Pain in elite athletes—neurophysiological, biomechanical and psychosocial considerations: a narrative review. *Br J Sports Med* 2017;51:1259–64.
- Heerey JJ, Kemp JL, Mosler AB, et al. What is the prevalence of hip intra-articular pathologies and osteoarthritis in active athletes with hip and groin pain compared with those without? A systematic review and meta-analysis. *Sports Med* 2019;49:951–72.
- Heerey JJ, Kemp JL, Mosler AB, et al. What is the prevalence of imaging-defined intra-articular hip pathologies in people with and without pain? A systematic review and meta-analysis. *Br J Sports Med* 2018;52:581–93.
- Reddy N, Martinez JR, Mulligan E, et al. Sleep quality and nocturnal pain in patients with femoroacetabular impingement and acetabular dysplasia. *BMC Musculoskelet Disord* 2020;21:134.
- Hampton SN, Nakonezny PA, Richard HM, et al. Pain catastrophizing, anxiety, and depression in hip pathology. *Bone Joint J* 2019;101-B:800–7.



- 40 Khanna V, Caragianis A, Diprimio G, *et al.* Incidence of hip pain in a prospective cohort of asymptomatic volunteers: is the cam deformity a risk factor for hip pain? *Am J Sports Med* 2014;42:793–7.
- 41 I R de Oliveira B, Smith AJ, O'Sullivan PPB, *et al.* 'My hip is damaged': a qualitative investigation of people seeking care for persistent hip pain. *Br J Sports Med* 2020;54:858–65.
- 42 O'Sullivan K, Darlow B, O'Sullivan P, *et al.* Imaging for hip-related groin pain: don't be hip-notised by the findings. *Br J Sports Med* 2018;52:551–2.
- 43 Weir A, Brukner P, Delahunt E, *et al.* Doha agreement meeting on terminology and definitions in groin pain in athletes. *Br J Sports Med* 2015;49:768–74.
- 44 Reiman MP, Agricola R, Kemp JL, *et al.* Consensus recommendations on the classification, definition and diagnostic criteria of hip-related pain in young and middle-aged active adults from the International hip-related pain research network, Zurich 2018. *Br J Sports Med* 2020;54:631–41.
- 45 Mascarenhas VV, Rego P, Dantas P, *et al.* Can we discriminate symptomatic hip patients from asymptomatic volunteers based on anatomic predictors? A 3-dimensional magnetic resonance study on cam, pincer, and spinopelvic parameters. *Am J Sports Med* 2018;46:3097–110.
- 46 Grammatopoulos G, Speirs AD, KCG N. Acetabular and spinopelvic morphologies are different in subjects with symptomatic cam femoro-acetabular impingement: acetabular and spinopelvic morphology in FAI. *J Orthop Res* 2018;36:1840–8.
- 47 Lee S, Nardo L, Kumar D, *et al.* Scoring hip osteoarthritis with MRI (SHOMRI): a whole joint osteoarthritis evaluation system. *J Magn Reson Imaging* 2015;41:1549–57.
- 48 Roemer FW, Hunter DJ, Winterstein A, *et al.* Hip osteoarthritis MRI scoring system (HOAMS): reliability and associations with radiographic and clinical findings. *Osteoarthritis Cartilage* 2011;19:946–62.
- 49 Horii M, Kubo T, Inoue S, *et al.* Coverage of the femoral head by the acetabular labrum in dysplastic hips: quantitative analysis with radial MR imaging. *Acta Orthop Scand* 2003;74:287–92.
- 50 Register B, Pennock AT, Ho CP, *et al.* Prevalence of abnormal hip findings in asymptomatic participants: a prospective, blinded study. *Am J Sports Med* 2012;40:2720–4.
- 51 Mineta K, Goto T, Wada K, *et al.* Comparison of femoroacetabular impingement-related radiographic features in a convenience sample of Japanese patients with and without herniation pits. *Skeletal Radiol* 2016;45:1079–88.
- 52 Anbar A, Ragab Y, Zeinhom F, *et al.* Cam versus pincer femoroacetabular impingement: which type is associated with more hip structural damage? an exploratory cross-sectional study. *Curr Orthop Pract* 2017;28:188–94.
- 53 Reiman MP, Thorborg K, Goode AP, *et al.* Diagnostic accuracy of imaging modalities and injection techniques for the diagnosis of femoroacetabular Impingement/Labral tear: a systematic review with meta-analysis. *Am J Sports Med* 2017;45:2665–77.
- 54 Saied AM, Redant C, El-Batouty M, *et al.* Accuracy of magnetic resonance studies in the detection of chondral and labral lesions in femoroacetabular impingement: systematic review and meta-analysis. *BMC Musculoskelet Disord* 2017;18:83.
- 55 Schleich C, Hesper T, Hosalkar HS, *et al.* 3D double-echo steady-state sequence assessment of hip joint cartilage and labrum at 3 tesla: comparative analysis of magnetic resonance imaging and intraoperative data. *Eur Radiol* 2017;27:4360–71.
- 56 Linda DD, Naraghi A, Murnaghan L, *et al.* Accuracy of non-arthrographic 3T MR imaging in evaluation of intra-articular pathology of the hip in femoroacetabular impingement. *Skeletal Radiol* 2017;46:299–308.
- 57 Chopra A, Grainger AJ, Dube B, *et al.* Comparative reliability and diagnostic performance of conventional 3T magnetic resonance imaging and 1.5T magnetic resonance arthrography for the evaluation of internal derangement of the hip. *Eur Radiol* 2018;28:963–71.
- 58 Gold GE, Cicuttini F, Crema MD, *et al.* OARS clinical trials recommendations: hip imaging in clinical trials in osteoarthritis. *Osteoarthritis Cartilage* 2015;23:716–31.
- 59 Leon AC, Heo M. Sample sizes required to detect interactions between two binary fixed-effects in a mixed-effects linear regression model. *Comput Stat Data Anal* 2009;53:603–8.